

## Technical Note

# A New Concept of Mosaicplasty: Autologous Osteoperiosteal Cylinder Graft Covered With Cellularized Scaffold

Murat Bozkurt, M.D., Ph.D., Ozgur Uysal, M.D., Erden Kilic, M.D., Fahri Emre, M.D., and Ozgur Kaya, M.D.

**Abstract:** A concern regarding osteochondral autograft transfer for chondral defects is donor-site morbidity of the knee, the most common source of the autograft. To avoid the drawbacks of osteochondral autograft transfer, a cylindrical osteoperiosteal graft harvested from the iliac crest covered by a same-sized cylinder of hyaluronic acid-based polymer scaffold pretreated with bone marrow aspirate concentrate and transferred to the chondral defect recipient site in the exact size for restoration of the subchondral bone and the articular cartilage.

### Introduction (With Video Illustration)

Although successful results have been reported by arthroscopic microfracture and abrasion arthroplasty for osteochondral lesions with subchondral defect of limited depth, large and deep subchondral defects or subchondral cysts may require restoration of the defect in the subchondral bone together with the articular cartilage.<sup>1-4</sup> Osteochondral autograft transfer (OAT) that includes transfer of cylinders from knee to ankle is a widely used technique for these types of lesions; however, donor-site morbidity is a major concern.<sup>2,4,5</sup> Highly variable rates have been reported for donor-site morbidity after knee-to-talus autologous

osteochondral transplantation, which ranges from 0% to 54.5% in short- to mid-term follow-up.<sup>5</sup>

In this technique, to avoid the drawbacks of osteochondral autograft transfer, a cylindrical osteoperiosteal graft harvested from iliac crest is covered by a same-sized cylinder of scaffold pretreated with bone marrow aspirate concentrate (BMAC) and transferred to the recipient site in the exact size for restoration of the subchondral bone and the articular cartilage (Video 1).

### Patient Evaluation, Imaging, and Indications

The technique can be employed in young patients with articular cartilage lesions severe enough to cause functional limitations, in whom the morbidity of OAT is also to be avoided. It is particularly of use for lesions that present with large subchondral cysts in computed tomography scans (Fig 1 A-C) and degeneration of the overlying cartilage in MRI (Fig 2 A-C).

### Surgical Technique

The surgical video is shown in Video 1. Standard ankle arthroscopy is performed through anteromedial and anterolateral portals. Examination of intraarticular structures with the probe may show softening of the articular cartilage. A curette may be introduced through the soft cartilage to evacuate the contents of the subchondral cyst. A mini-incision may be performed to expose the joint. The margins of the cyst and the damaged part of the articular cartilage that has been marked during arthroscopy is sharply delineated with a scalpel and all the contents of the cyst are removed by a

*From the Department of Orthopaedics and Traumatology, School of Medicine, Ankara Yildirim Beyazit University (M.B.); Orthopaedics Clinic, Ankara Yuzuncu Yil Hospital (O.U., E.K.); Department of Orthopaedics and Traumatology, Gulhane Training and Research Hospital (F.E.); and Department of Orthopaedics and Traumatology, School of Medicine, Lokman Hekim University, (O.K.), Ankara, Turkey.*

*The authors report that they have no conflicts of interest in the authorship and publication of this article. Full ICMJE author disclosure forms are available for this article online, as supplementary material.*

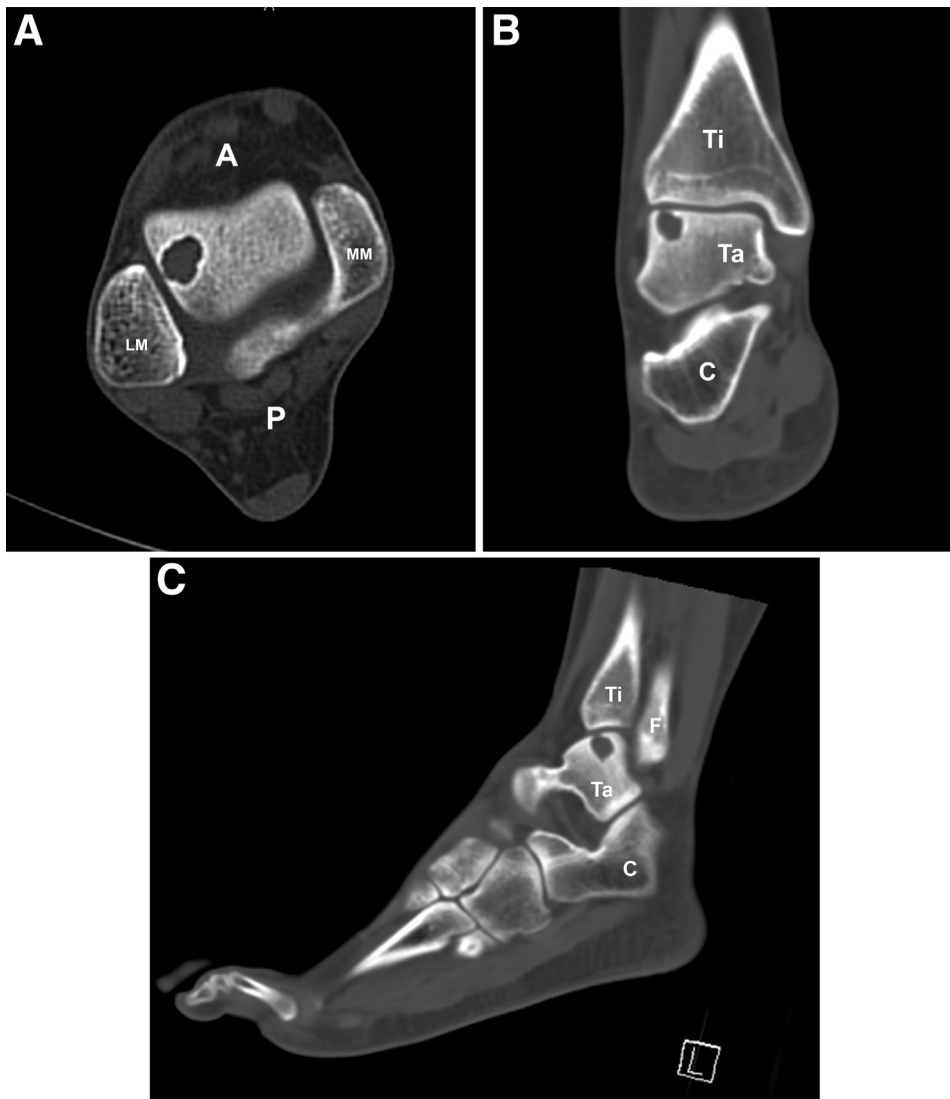
*Received October 10, 2021; accepted December 14, 2021.*

*Address correspondence to Prof. Dr. Murat Bozkurt, Mahall Ankara Mustafa Kemal Mah. Dumlupinar Bul. No: 274 B Blok 12 Kat No: 131, 06530, Cankaya/Ankara. E-mail: nmbozkurt@gmail.com*

© 2022 THE AUTHORS. Published by Elsevier Inc. on behalf of the Arthroscopy Association of North America. This is an open access article under the CC BY-NC-ND license (<http://creativecommons.org/licenses/by-nc-nd/4.0/>).

2212-6287/211496

<https://doi.org/10.1016/j.eats.2021.12.033>



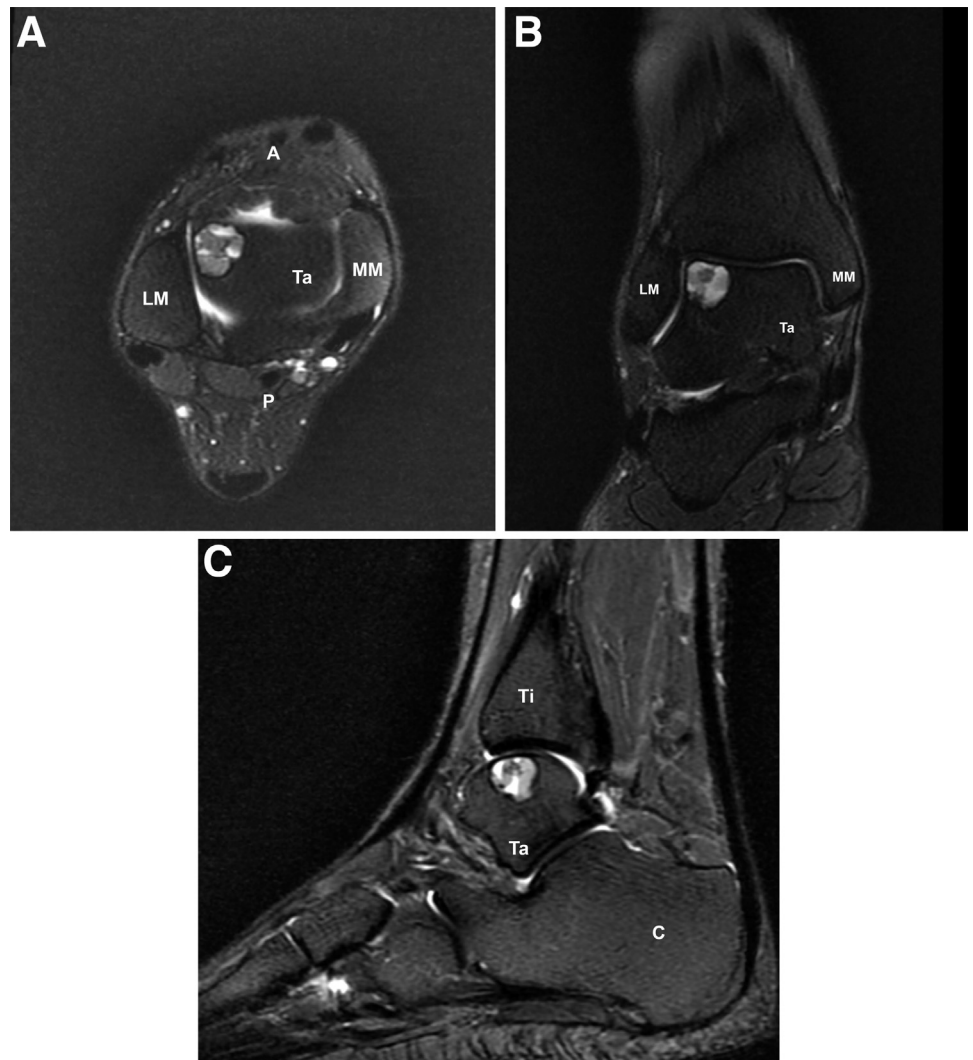
**Fig 1.** (A-C) Axial, coronal, and sagittal computed tomography images of the talar subchondral cyst (A, anterior; C, calcaneus; F: Fibula; LM, lateral malleol; MM, medial malleol; P, posterior; Ta, Talus; Ti, Tibia.)

curette (Fig 3). The recipient area is prepared by an appropriate size of Osteoarticular Transfer System trephine (10 mm), which is introduced to a depth of 15 mm, in this patient while the ankle was in plantar flexion (Fig 4). Then, the wound is closed with a saline-dampened sponge and the iliac crest is prepared for graft harvest. After a mini-incision on skin and subcutaneous tissue of the iliac crest, an osteoperiosteal cylinder of 15 mm deep with its overlying periosteum is removed from the posterior iliac crest using a 10-mm donor harvester (Fig 5). The graft is then extruded and trimmed as 12 mm. The ankle is re-exposed, recipient field is irrigated, and after a nanofracture is performed at the base, the graft is inserted into the defect until its upper surface is 3 mm lower than the cartilage level (Fig 6). Meanwhile on the surgical side, the anterior iliac crest is prepared for harvesting of the BMAC. Bone marrow of 60 mL was aspirated through

the bone marrow aspiration needle and the aspirate is concentrated by BMAC2-60-01 procedure pack (Macallan Terumo, Plymouth, MA) of the Harvest BMAC Cellular Therapy System. This system usually produces 7 to 10 mL of mesenchymal stem cells. This BMAC is then injected to the cylindrical hyaluronic acid-based polymer scaffold (CARTILAGO MATRIX; Biolot Medical, Ankara, Turkey) and kept soaked for several minutes (Fig 7). The scaffold is dried and placed on the surface and fixed by fibrin glue (Tissel 4 mm; Baxter, Deerfield, IL). After waiting for 4 minutes, stability of graft is confirmed by gentle joint movements. Layers of the wound are closed accordingly, and a compressive bandage is applied to the joint (Table 1).

### Rehabilitation

On the first postoperative day, patient is instructed by a physical therapist in passive and active range of

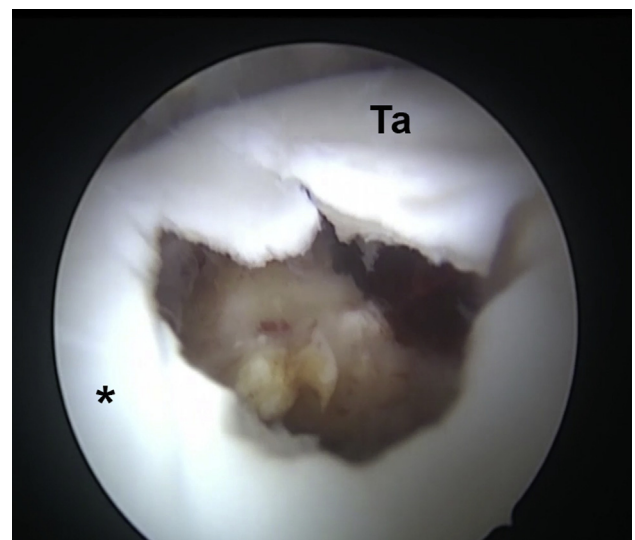


**Fig 2.** (A-C) Magnetic resonance imaging frames show the size of subchondral cyst and cartilage involvement. (A, anterior; C, calcaneus; LM, lateral malleol; MM, medial malleol; P, posterior; Ta, Talus; Ti, Tibia.)

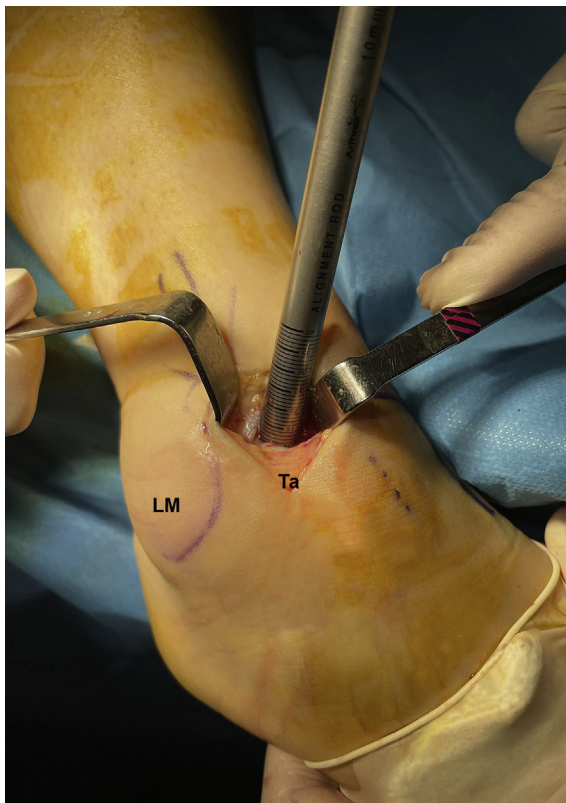
motion exercises of hip, knee, and ankle joint in bed (15 minutes, 3 times a day). Patients are not allowed to weight bear on the affected limb for 6 weeks after surgery, and partial weight-bearing is allowed thereafter. Full weight-bearing is allowed at 8 weeks after surgery,

### Discussion

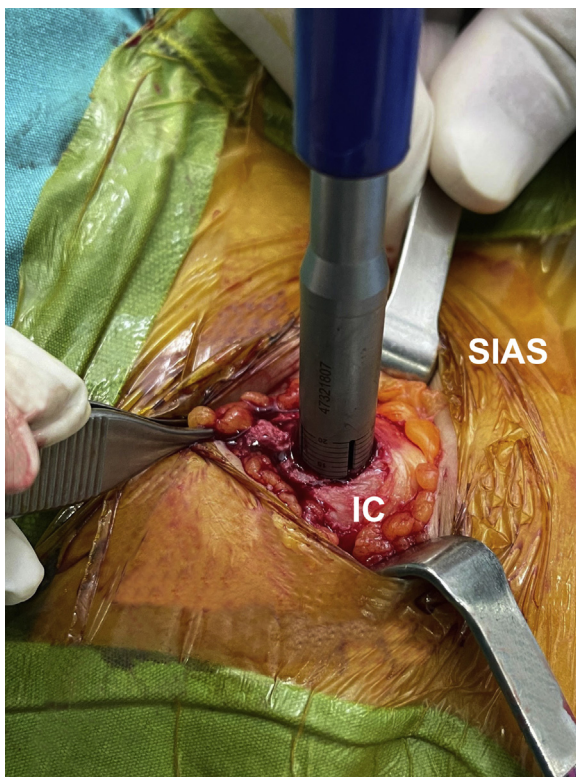There are various methods reported for the treatment of osteochondral lesions of the ankle.<sup>3,4,6</sup> Anatomic and biomechanical characteristics of the ankle joint and the structure of the articular cartilage significantly differs from the knee joint. Thus, the treatment methods also should be different. Studies have shown the efficacy of the microfracture or nanofracture in the treatment of osteochondral lesions with limited involvement of the subchondral bone.<sup>3,6</sup> Although Lee et al.<sup>3</sup> reported satisfactory results after microfracture in both groups involving the osteochondral lesions with or without the



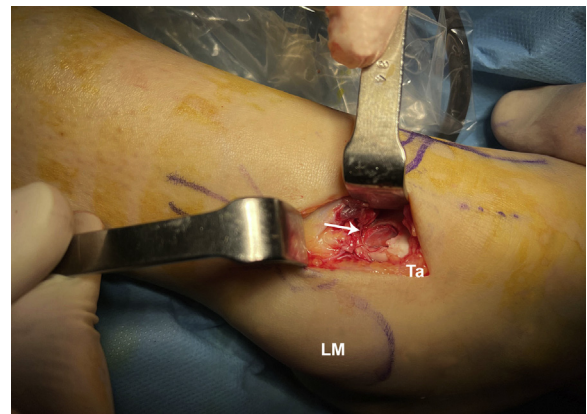
**Fig 3.** Arthroscopic view of the cavity of the cyst. \*Lateral side of articular surface of the talus) (Ta, talus.)



**Fig 4.** Preparation of the recipient area (LM, lateral malleol; Ta, talus.)

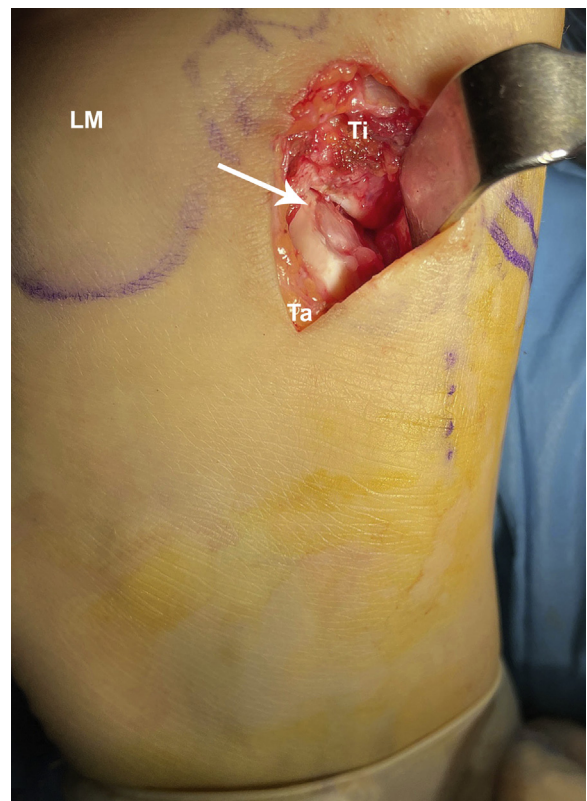


**Fig 5.** Osteoperiosteal cylindrical graft harvesting (IC, iliac crest; SIAS, spina iliaca anterior superior.)



**Fig 6.** Insertion of the osteoperiosteal cylindrical graft to the recipient area. white arrow shows graft. (LM, lateral malleol; Ta, talus.)

presence of cysts, their study included small to mid-size cysts. In the study of Yang and Lee,<sup>7</sup> arthroscopic microfracture provided functional improvements, but second-look arthroscopies revealed that 36% of lesions were incompletely healed and a repair tissue of inferior quality compared with that of native cartilage was observed at a mean follow-up of 3.6 years. Choi et al.<sup>8</sup>



**Fig 7.** BMAC soaking collagen-hyaluronic acid scaffold application to the surface of the osteoperiosteal graft. white arrow shows graft. (BMAC, bone marrow aspirate concentrate; LM, lateral malleol; Ta, talus; Ti, tibia.)

**Table 1.** Surgical Steps

---

Surgical preparations of the ankle and same side iliac wing
Ankle portal placement
Identification of the lesion
Debridement of damaged cartilage and curettage of the cyst
Microfracture of the base of the lesion
Recipient area preparation of the talus
Harvesting of osteoperiosteal cylindrical plugs from iliac wing
Placement of the osteoperiosteal graft to the talus
Scaffold preparation for cylindrical graft
BMAC soaking of the scaffold
Placement of the scaffold to the top of the osteoperiosteal graft
Apply fibrin glue over the top of the scaffold
Hold in place until fibrin glue sets (5-7 min)
Graft stability control with ankle movements

---

BMAC, bone marrow aspirate concentrate.

noted that arthroscopic microfracture seems to be reliable as the first-line treatment of osteochondral lesions at an intermediate-term follow-up. However, several studies have reported inferior outcomes when lesion size is greater than 150 mm<sup>2</sup>. OAT has been suggested to be a reliable and effective treatment option for the lesions sized 150 to 400 mm<sup>2</sup>.<sup>9,10</sup> The goal of OAT is to provide an autologous bone plug(s) to fit and fill the osteochondral defect. A recent meta-analysis of OAT

**Table 2.** Pearls and Pitfalls

---

Pearls
Lesion localizations and size defined in preoperative MRI to select portal placement and arthroscopic application
Mini-open exposure to the ankle
Cartilage debridement to define the lesion
Curettage of the cyst to get healthy subchondral bone
Recipient area preparation with mosaicplasty trephine more than 10 mm depth
Microfracture or nanofracture of the base of the lesion to test subchondral bone quality and bleeding
Osteoperiosteal graft harvesting with mosaicplasty set in the iliac crest same depth with recipient area depth
Scaffold preparations according to the osteoperiosteal cylindrical graft surface size.
BMAC soaking and injecting to the scaffold
BMAC injection to the subchondral bone on the base of lesion
Osteoperiosteal graft application 2-3 mm deep to the healthy cartilage surface level
Scaffold application to the surface and fibrin glue fixation at the border of the graft
Pitfalls
It should be kept in mind that it will be difficult to provide sufficient depth in the subchondral bone in the lower part of the cyst in the preparation of the recipient area.
The length of the osteoperiosteal graft harvested from the iliac crest should be prepared to be 2-3 mm below the cartilage level in the talus.
Must be tested before placing the cartilage to be 2-3 mm, depending on the depth in the talus.
Because of the soft structure of the scaffold, the proper size and shape to be placed on top of the cylindrical graft can be difficult to prepare.

---

BMAC, bone marrow aspirate concentrate; MRI, magnetic resonance imaging.

procedures for talar defects demonstrated a significant improvement of American Orthopaedic Foot and Ankle Society scores with 87.4% of patients reporting excellent or good results.<sup>4</sup>

It is important to evaluate the structural stability of the subchondral bone. Formation of the fibrocartilage may not be accompanied by subchondral bone development after the use of marrow-stimulating techniques, particularly if the subchondral bone quality is disturbed and cannot provide a solid scaffold for the overlying cartilage.<sup>11,12</sup> OAT, which provides healthy subchondral bone with hyaline cartilage, may be considered as the ideal treatment; however, problems arise due to surgical intervention in a healthy joint, and donor-site morbidity emphasized in many studies is the major disadvantage of this method. Matrix autologous chondrocyte implantation, a 2-stage treatment that frequently is employed with bone grafting, is a stressful procedure for the patient, with substantial costs.<sup>13-18</sup> Another alternative that may be used is the osteochondral allografts, but problems like difficulty in its availability, greater costs, and demanding procedures hinder its routine use. According to Hu et al.,<sup>19</sup> osteoperiosteal cylindrical grafts obtained from iliac crest may exhibit less chondrogenesis, since the periosteum lacks the cambium layer. Therefore, in the method described, we use the osteoperiosteal cylinder of subchondral bone and tidemark covered with a cellular scaffold to stimulate chondrogenesis (Table 2).

This method we describe is a simple, safe, and effective method also to be used in all joints. Clinical results of case series consisting of the patients on which this technique will be used, and also comparative studies, are required to support our hypothesis.

## References

1. Cao Y, Xu Y, Huang Q, Hong Y, Xu X. Characteristics of osteochondral lesions of the talus in different age groups. *Int J Sports Med* 2020;41:873-878.
2. Filardo G, Kon E, Perdisa F, Balboni F, Marcacci M. Autologous osteochondral transplantation for the treatment of knee lesions: Results and limitations at two years' follow-up. *Int Orthop* 2014;38:1905-1912.
3. Lee KB, Park HW, Cho HJ, Seon JK. Comparison of arthroscopic microfracture for osteochondral lesions of the talus with and without subchondral cyst. *Am J Sports Med* 2015;43:1951-1956.
4. Nguyen A, Ramasamy A, Walsh M, McMenemy L, Calder J. Autologous osteochondral transplantation for large osteochondral lesions of the talus is a viable option in an athletic population. *Am J Sports Med* 2019;47:3429-3435.
5. Shimozone Y, Seow D, Yasui Y, Fields K, Keneddy JG. Knee-to-talus donor-site morbidity following autologous osteochondral transplantation: A meta analysis with best-case and worst-case analysis. *Clin Orthop* 2019;477:1915-1931.

6. Tahta M, Akkaya M, Gursoy S, Isik C, Bozkurt M. Arthroscopic treatment of osteochondral lesions of the talus. Nanofracture versus hyaluronic acid-based cell-free scaffold with concentration of autologous bone marrow aspirate. *J Orthop Surg* 2017;25:1-5.
7. Yang HY, Lee KB. Arthroscopic microfracture for osteochondral lesions of the talus: Second-look arthroscopic and magnetic resonance analysis of cartilage reapiar tissue outcomes. *J Bone Joint Surg Am* 2020;102:10-20.
8. Choi SW, Lee GW, Lee KB. Arthroscopic microfracture for osteochondral lesions of the talus: Functional outcomes at a mean of 6.7 years in 165 consecutive ankles. *Am J Sports Med* 2020;48:153-158.
9. Deng E, Shi W, Jiang Y, Guo Q. Comparison of autologous osteoperiosteal cylinder and osteochondral graft transplantation in the treatment of large cystic osteochondral lesions of the talus (OLTs): A protocol for non-inferiority randomised controlled trial. *BMJ Open* 2020;10:e033850.
10. Chen W, Tang K, Yuan C, Zhou Y, Tao X. Intermediate results of large cystic medial osteochondral lesions of the talus treated with osteoperiosteal cylinder autografts from the medial tibia. *Arthroscopy* 2015;31:1557-1564.
11. Nakasa T, Adachi N, Kato T, Ochi M. Appearance of subchondral bone in computed tomography is related to cartilage damage in osteochondral lesions of the talar dome. *Foot Ankle Int* 2014;35:600-606.
12. Madry H, van Dijck CN, Mueller-Gerbl M. The basic science of the subchondral bone. *Knee Surg Sports Traumatol Arthrosc* 2010;18:419-433.
13. Deng C, Chang J, Wu C. Bioactive scaffolds for osteochondral regeneration. *J Orthop Translat* 2018;26:15-25.
14. Baltzer AWA, Arnold JP. Bone-cartilage transplantation from ipsilateral knee for chondral lesions of the talus. *Arthroscopy* 2005;21:159-166.
15. Gao L, Orth P, Cucchiarini M, Madry H. Autologous matrix-induced chondrogenesis: A systematic review of the clinical evidence. *Am J Sports Med* 2019;47:222-231.
16. Lenz CG, Tan S, Carey AL, Ang K, Schneider T. Matrix-induced autologous chondrocyte implantation (MACI) grafting for osteochondral lesions of the talus. *Foot Ankle Int* 2020;41:1099-1105.
17. Luick L, Steinmetz G, Haleem A. All-arthroscopic osteochondral autograft transfer technique for osteochondritis dissecans of the talus. *Arthrosc Tech* 2020;9:499-503.
18. Nakagawa Y, Suzuki T, Matsusue Y, Kuroki H, Mizuno Y, Nakamura T. Bony lesion recurrence after mosaicplasty for osteochondritis dissecans of the talus. *Arthroscopy* 2005;21:630.
19. Hu Y, Guo Q, Jiao C, Jiang D, Wang J, Zheng Z. Treatment of large cystic medial osteochondral lesions of the talus with autologous posteoperiosteal clinder grafts. *Arthroscopy* 2013;29:1372-1379.